



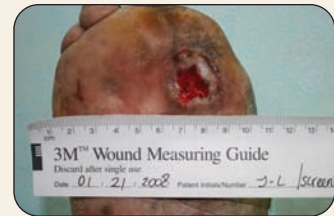
Three-Month-Old Neuropathic Ulcer

JL is a 70-year-old African American male with a 10-year history of diabetes mellitus. He has a history of prior toe amputations on both feet. He presented with a 3-month-old, classic neuropathic ulcer. Prior treatments consisted of daily changes of wet to dry dressings, weekly sharp debridement and Prisma®.

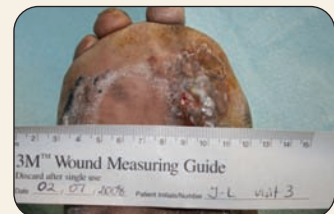JL was treated with Healadex® Wound Dressing, weekly sharp debridement, off-loading with a felt/foam padding and a post-operative shoe. Dressings were changed every 3 days.

About Healadex Wound Dressings

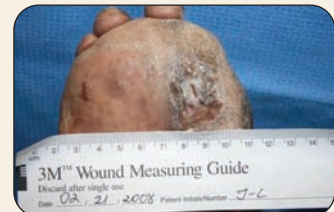Healadex is the advanced approach to moist dressings developed by Healagenics for the treatment of acute and chronic wounds. The FDA-cleared Healadex contains porcine serum and offers clinicians a new option to jump start the healing process.



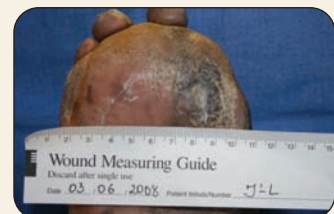
BASELINE



WEEK 1



WEEK 3



WEEK 5



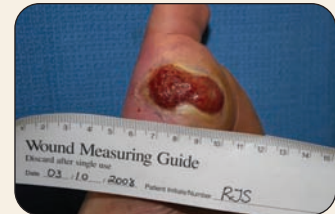Four-Month-Old Neuropathic Ulcer

RS is a 53-year-old Caucasian, non-diabetic male with severe neuropathy. He has a neuropathic ulcer, sub-1st metatarsal head that has been present for 4 months. Prior treatments consisted of 6 weeks of IV antibiotics, weekly debridement and off-loading with a post-operative shoe.

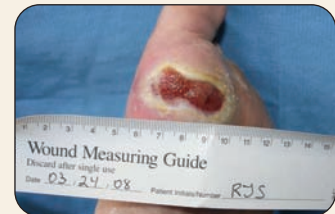RS was treated with Healadex[®] Wound Dressing and off-loading using a removable boot. The wound received weekly sharp debridement and dressings were changed every 3 days. The secondary dressing was appropriately sized gauze and Kling roll.

About Healadex Wound Dressings

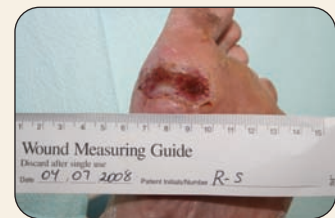Healadex is the advanced approach to moist dressings developed by Healagenics for the treatment of acute and chronic wounds. The FDA-cleared Healadex contains porcine serum and offers clinicians a new option to jump start the healing process.



BASELINE



WEEK 2



WEEK 4



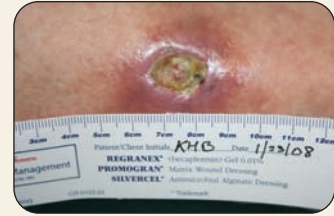Six-Month-Old Leg Ulcer

KB is a 60-year-old Caucasian male with a 10-year history of diabetes mellitus. He presented with a 6-month-old, non-healing leg ulcer. Prior treatments included daily wet to dry dressings and enzymatic debridement with Accuzyme®.

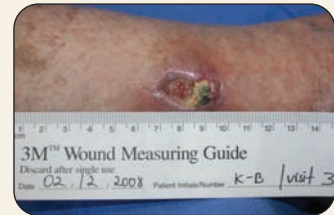KB received weekly sharp debridement and the Healadex® Wound Dressings were changed every 3 days. The secondary dressing was appropriately-sized gauze and Kerlix roll.

About Healadex Wound Dressings

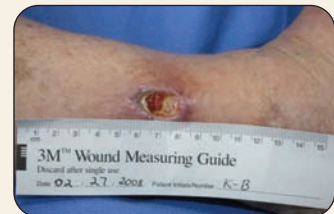Healadex is the advanced approach to moist dressings developed by Healagenics for the treatment of acute and chronic wounds. The FDA-cleared Healadex contains porcine serum and offers clinicians a new option to jump start the healing process.



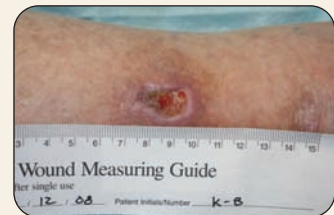BASELINE



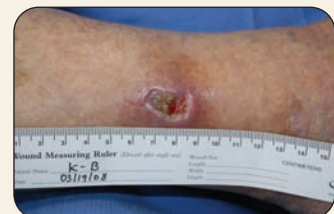WEEK 1



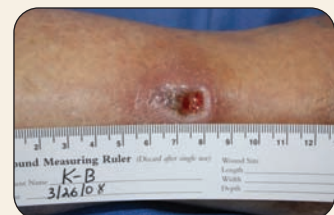WEEK 3



WEEK 5



WEEK 6



WEEK 8



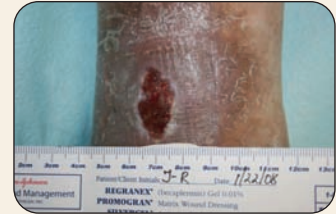Two-Year-Old Ulcer

JR is a 38-year-old Caucasian male with no history of diabetes mellitus. His ulcer has been present for 2 years. Prior treatments have consisted of weekly compression dressings (Profore, Unna boot/Coban), Prisma® and weekly sharp debridement. The prior treatments did not result in any progress towards healing the wound.

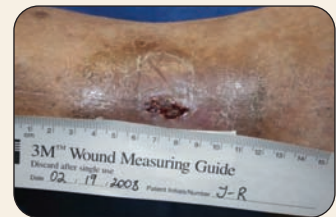JR was treated with Healadex® Wound Dressing. Debridement was not needed. The wound was cleansed with normal saline prior to the dressing change. Dressings were changed every 3 days. The secondary dressing was appropriately-sized gauze and Kling roll.

About Healadex Wound Dressings

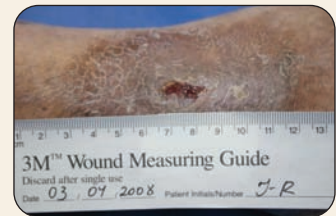Healadex is the advanced approach to moist dressings developed by Healagenics for the treatment of acute and chronic wounds. The FDA-cleared Healadex contains porcine serum and offers clinicians a new option to jump start the healing process.



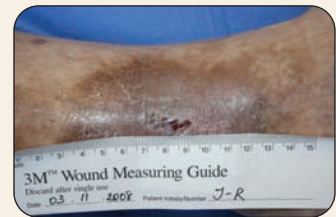BASELINE



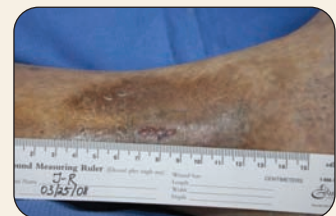WEEK 1



WEEK 3



WEEK 4



WEEK 6